

Letters to the Editor

Venlafaxine in a Patient With Idiopathic Leukopenia and Mirtazapine-Induced Severe Neutropenia

Sir: Severe neutropenia, defined as less than $0.5 \times 10^9/L$ mature neutrophil cells, is a potentially life-threatening side effect with tricyclic antidepressants,¹ but it also occurs with mirtazapine with an approximate risk of up to 1 in 1000.² Here, we present a patient with a known idiopathic leukopenia and cross-intolerance between tricyclic antidepressants and mirtazapine who developed agranulocytosis with mirtazapine. After discontinuation of mirtazapine, she was safely treated with venlafaxine.

Case report. Ms. A, a 64-year-old woman with a history of DSM-IV major depressive disorder, was admitted to our hospital because of a severe major depressive episode with transient psychotic features. Her white blood cell count (WBC) had varied over the past 7 years between $3.5 \times 10^9/L$ and $4.0 \times 10^9/L$. In the past, a bone marrow biopsy had revealed a normal distribution of the leukocyte subtypes. With her lack of clinical predisposition to infections, the assumptive diagnosis had been benign idiopathic leukopenia. In 1992, Ms. A had been treated for the first time with tricyclic antidepressants such as doxepin and amitriptyline. With each medication, she developed neutropenia with a WBC of about $2.0 \times 10^9/L$ and a neutrophil count of $0.4 \times 10^9/L$. Her major complaints at this admission were psychomotor agitation and sleep disturbance. Therefore, she received mirtazapine, 15 mg at bedtime. Because of the known former agranulocytotic reactions, the WBC was measured the next morning, 12 hours after the ingestion of mirtazapine. The WBC had dropped from $3.8 \times 10^9/L$ (1 day before) to $1.4 \times 10^9/L$ with a neutrophil count of only $0.3 \times 10^9/L$. The other leukocyte subtype counts remained stable. Mirtazapine was discontinued and venlafaxine was given in dosages up to 375 mg/day. This procedure was well tolerated. Ms. A's neutrophil level recovered and her WBC ranged afterwards between $3.5 \times 10^9/L$ and $4.2 \times 10^9/L$ as determined by monthly control measurements over a period of 12 months.

To our knowledge, this is the first report of the safe use of venlafaxine in a patient with agranulocytosis induced by mirtazapine. In our patient, idiopathic leukopenia had been diagnosed before, so a predisposition for agranulocytosis might have existed. Moreover, she had experienced agranulocytoses due to tricyclic antidepressants in the past. Cross-intolerance between 2 tricyclics has been described before in at least 1 case report.³ One might assume that tetracyclics such as mirtazapine could cause agranulocytosis by similar mechanisms as tricyclics and that cross-intolerance might occur between these different classes of drugs. Because of the rather fast kinetics of the fall in neutrophil counts (within hours), an immunologic process after sensitization in the past seems most likely. In contrast, venlafaxine is not known to be associated with a significantly

increased risk of neutropenia or agranulocytosis.⁴ Accordingly, venlafaxine was well tolerated in our patient.

A limiting factor to our findings could be that the patient might have had a congenital cyclic neutropenia,⁵ so that the neutropenia could have occurred spontaneously. Nevertheless, this diagnosis seems very unlikely because the patient had a quite stable WBC and, after mirtazapine's discontinuation, never again experienced as low a WBC. In addition to cyclic neutropenia, one should consider pseudoneutropenia as a differential diagnosis that can mislead the unwary clinician.

The authors report no financial affiliation or other relationship relevant to the subject matter of this letter.

REFERENCES

1. Albertini RS, Penders TM. Agranulocytosis associated with tricyclics. *J Clin Psychiatry* 1978;39:483-485
2. Hartmann PM. Mirtazapine: a newer antidepressant. *Am Fam Physician* 1999;59:159-161
3. Draper BM, Manoharan A. Neutropenia with cross-intolerance between two tricyclic antidepressant agents. *Med J Aust* 1987;146:452-453
4. Rudolph RL, Derivan AT. The safety and tolerability of venlafaxine hydrochloride: analysis of the clinical trials database. *J Clin Psychopharmacol* 1996;16:54S-59S
5. Souid AK. Congenital cyclic neutropenia. *Clin Pediatr* 1995;34:151-155

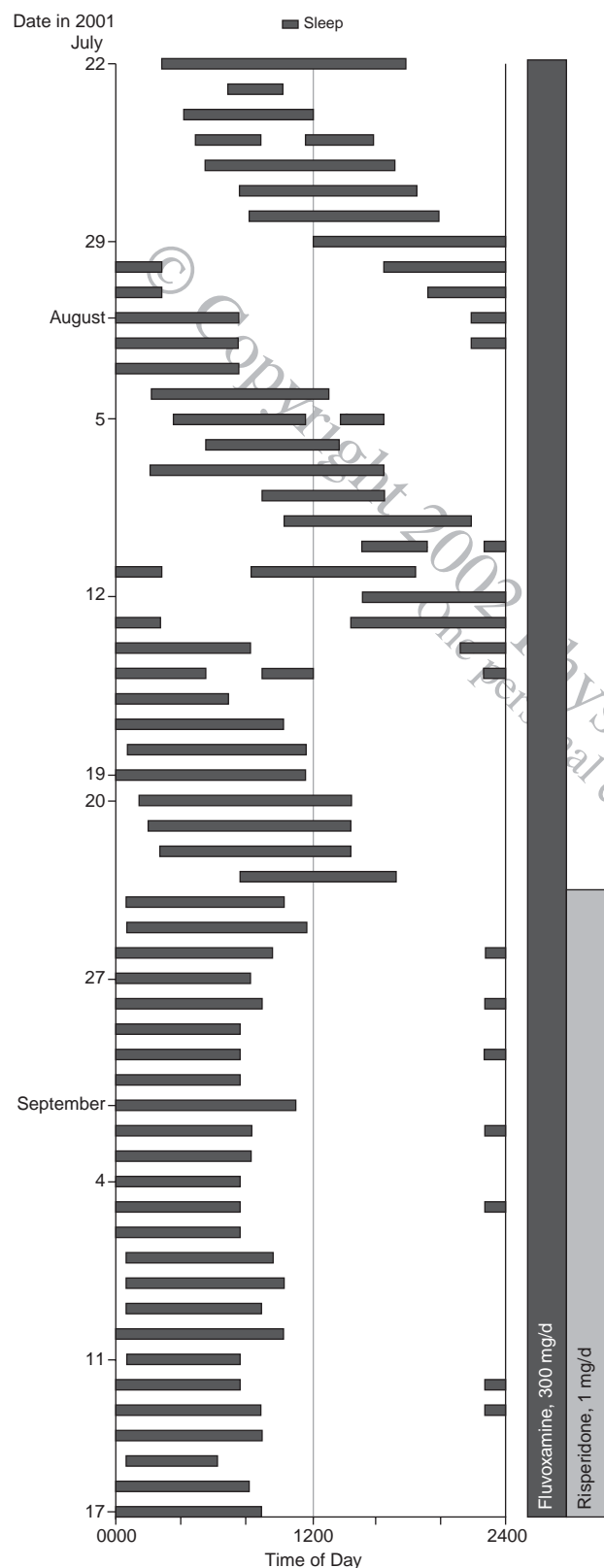
Ion Angheliescu, M.D.
Free University Berlin
Berlin, Germany
Christoph Klawe, M.D.
Norbert Dahmen, M.D.
University of Mainz
Mainz, Germany

Obsessive-Compulsive Disorder With Non-24-Hour Sleep-Wake Syndrome

Sir: Previous reports have indicated that risperidone augmentation of serotonin reuptake inhibitor (SRI) treatment is effective in patients with SRI-resistant obsessive-compulsive disorder (OCD).¹⁻³ Moreover, improvement in the quality of sleep by risperidone is increasingly reported.^{4,5} We present a case of a male OCD patient with non-24-hour sleep-wake syndrome who experienced a marked reduction in OCD symptoms as well as sleep-wake disturbance by the addition of risperidone to fluvoxamine.

Case report. Mr. A, a 22-year-old man, was referred to Hiroshima (Japan) University Hospital due to refractory OCD. He had severe checking compulsions and mild obsessive

Figure 1. Sleep-Wake Cycle Before and After Administration of Risperidone, 1 mg^a



^aRisperidone administered between 2200 and 2300.

thoughts. For example, he checked over 20 times when unsure whether he correctly turned off a faucet. His total score on the Yale-Brown Obsessive Compulsive Scale (YBOCS) was 26. Although his symptoms met the criteria for OCD in the DSM-IV classification, treatment with fluvoxamine at 300 mg/day for 1 month resulted in no improvement.

In addition, he complained of difficulty falling asleep and arising at a socially desirable time that had lasted for 2 years. Since we considered that his sleep disturbance was not due to fluvoxamine, we asked him to keep a sleep diary. The result of his sleep diary for 2 months indicated a free-running sleep-wake cycle (Figure 1). He was diagnosed as having obsessive-compulsive disorder with circadian rhythm sleep disorder, unspecified type (according to DSM-IV criteria), or non-24-hour sleep-wake disorder (identified using the *International Classification of Sleep Disorders*⁶).

Although we recommended a treatment regimen of phototherapy and melatonin administration, the subject refused our treatment proposal and requested an additional pharmacotherapy for OCD. Therefore, 1 mg of risperidone was added to his regimen at bedtime. Within 2 weeks after the addition of risperidone, his YBOCS total score decreased to 12 and his disturbance of sleep-wake cycle almost remitted. Apparently, risperidone entrained his sleep-wake cycle to a 24-hour day (Figure 1). As the discontinuation of risperidone resulted in recurrence of non-24-hour sleep-wake syndrome, it is evident that risperidone was effective.

To our knowledge, there have been no reports describing either a case of OCD with non-24-hour sleep-wake syndrome or the efficacy of coadministration of risperidone with fluvoxamine in the treatment of non-24-hour sleep-wake syndrome. Recent pharmacologic studies of circadian rhythms have indicated that melatonin as well as serotonin (5-HT) in the suprachiasmatic nucleus (SCN) plays an important role in the mechanism of circadian rhythms. The activation of 5-HT₇ receptors in the SCN is reported to result in non-light-induced entrainment.⁷ In contrast, it is known that risperidone has a relatively high affinity for the 5-HT₇ receptor.⁸ Although the precise mechanism for the efficacy of risperidone in the treatment of non-24-hour sleep-wake syndrome is unknown, the 5-HT₇ receptor blockade by risperidone may be, at least in part, related.

In addition, it has been recently revealed that since the cytochrome P450 1A2 isoenzyme is almost exclusively involved in the metabolism of melatonin,^{9,10} fluvoxamine inhibits melatonin degradation. In fact, Grözinger and colleagues¹¹ demonstrated that the administration of fluvoxamine increases the serum concentrations of melatonin in a patient with chronic primary insomnia. It is conceivable that both the 5-HT₇ receptor blockade by risperidone and the inhibition of melatonin metabolism by fluvoxamine may play a role in the treatment of non-24-hour sleep-wake syndrome. Further studies are required to evaluate the efficacy of a coadministration of risperidone with fluvoxamine on non-24-hour sleep-wake syndrome.

From our findings, psychiatrists should be aware of the possibility of the comorbidity of OCD and circadian rhythm sleep disorder. Therefore, the sleep diary has a beneficial effect to identify patients with OCD accompanied by circadian rhythm sleep disorder.

REFERENCES

1. McDougle CJ, Fleischmann RL, Epperson CN, et al. Risperidone addition in fluvoxamine-refractory obsessive-compulsive disorder: three cases. *J Clin Psychiatry* 1995;56:526-528
2. McDougle CJ, Epperson CN, Pelton GH, et al. A double-blind,

- placebo-controlled study of risperidone addition in serotonin reuptake inhibitor–refractory obsessive-compulsive disorder. *Arch Gen Psychiatry* 2000;57:794–801
3. Stein DJ, Bouwer C, Hawkrigde S, et al. Risperidone augmentation of serotonin reuptake inhibitors in obsessive-compulsive and related disorders. *J Clin Psychiatry* 1997;58:119–122
 4. Dursun SM, Patel JKM, Burke JG, et al. Effects of typical antipsychotic drugs and risperidone on the quality of sleep in patients with schizophrenia. *J Psychiatr Neurosci* 1999;24:333–337
 5. Schreiber S, Klag E, Gross Y, et al. Beneficial effect of risperidone on sleep disturbance and psychosis following traumatic brain injury. *Int Clin Psychopharmacol* 1998;13:273–275
 6. American Sleep Disorders Association. *The International Classification of Sleep Disorders*. Lawrence, Kan: Allen Press; 1990
 7. Horikawa K, Yokota S, Fuji K, et al. Nonphotic entrainment by 5-HT_{1A/7} receptor agonists accompanied by reduced Per1 and Per2 mRNA levels in the suprachiasmatic nuclei. *J Neurosci* 2000;20:5867–5873
 8. Roth BL, Craig SC, Choudhary MS, et al. Binding of typical antipsychotic agents to 5-hydroxytryptamine-6 and 5-hydroxytryptamine-7 receptors. *J Pharmacol Exp Ther* 1994;268:1403–1410
 9. Facciola G, Hidestrand M, von Bahr C, et al. Cytochrome P450 isoforms involved in melatonin metabolism in human liver microsomes. *Eur J Clin Pharmacol* 2001;56:881–888
 10. Härter S, Wang X, Weigmann H, et al. Differential effects of fluvoxamine and other antidepressants on the biotransformation of melatonin. *J Clin Psychopharmacol* 2001;21:167–174
 11. Grözinger M, Härter S, Wang X, et al. Fluvoxamine strongly inhibits melatonin metabolism in a patient with low-amplitude melatonin profile [letter]. *Arch Gen Psychiatry* 2000;57:812–813

Shigeru Morinobu, M.D., Ph.D.

Hidehisa Yamashita, M.D.

Shigeto Yamawaki, M.D., Ph.D.

Hiroshima University School of Medicine
Hiroshima, Japan

Kazuhide Tanaka, M.D.

Masako Ohkawa, M.D., Ph.D.

Shiga University of Medical Sciences
Otsu, Japan

Injection of Depot Antipsychotic Medications in Patients With Schizophrenia

Sir: I read with great interest the article “Injections of Depot Antipsychotic Medications in Patients Suffering From Schizophrenia: Do They Hurt?”¹ published recently in the *Journal*.

First, a very minor point in the title: It is not clear whether the “They” in the title refers to the patients or the injections. Second, a not-so-minor point in the conclusion: The authors conclude that “antipsychotic injections cause pain in patients suffering from schizophrenia.”^(pp858–859) I would amend this conclusion to read “antipsychotic medications, *if improperly administered*, can cause pain in patients suffering from schizophrenia.” This is an important point, because the impact of the article inevitably will be to discourage physicians from using i.m. injectable depot medications. Such discouragement would be most unfortunate. It is widely acknowledged that depot medications are an effective way of treating many patients, and for some patients they spell the difference between hospitalizations and a successful community adjustment. Although mild pain may be an accompaniment of any injection, the pain should never be severe with proper injection technique. In fact, I have had some patients who prefer injections to oral administrations.

Although the authors were very conscientious in their use of the patient assessment tools (the Clinical Global Impressions scale, the Brief Psychiatric Rating Scale, the Hamilton Rating

Scale for Depression, the Hamilton Rating Scale for Anxiety, and the Extrapyramidal Symptom Rating Scale), one cannot help but wonder if all these assessment scales were really necessary to prove that i.m. medications can hurt. Unfortunately, little was said about the technique of administration of the i.m. medications, a factor that may be more important than any of the aforementioned scales.

The authors state that all of the injections were administered by the same nurse in the same setting. I understand that this reference is in the interest of controlling all possible contaminating factors, but could it be that the same nurse may be making the same mistakes in the same setting? We do not know if this is true because the description of the technique of administration is incomplete. The authors state that “all patients received their medication in the gluteus, using a 0.1-mL air lock” and that “the dosage (mg) and volume (mL) of the injected substance were recorded for each patient.”^(p856) What is omitted from the description is much more important than the description of the syringe. We need to know information about the bore of the needle (the larger the bore, the more likely that pain will accompany the injection), the speed of the injection (rapid injections are associated with increased pain), and the precise location of the injection site. Although the authors specify the gluteus as the sole injection site, an injection to the medial aspect of the gluteus can stimulate the sciatic nerve, producing the kind of intense pain that the authors describe in the article: “all patients reported on the ‘worst pain ever due to a depot injection.’”

My own experiences with administering i.m. depot injections are restricted to fluphenazine decanoate and haloperidol decanoate and involve thousands of injections over a period of 25 years. I have no experience with i.m. zuclopenthixol or flupenthixol insofar as these preparations are rarely—if ever—used in the United States.

Somewhere in some textbook there is probably a paragraph that addresses the problem of how to administer an i.m. medication. So far I have yet to find it. The following recommendations are based on my own experiences.

First, I prefer the deltoid to the gluteus. The authors state that all injections were to the gluteus. Why? The authors are concerned about pain. The deltoid, when properly addressed, may or may not be less painful to the patient, but injection to the deltoid is certainly less of a painfully embarrassing experience. Injections to the deltoid are best administered to the posterior aspect of the deltoid, where it is least painful. I generally aim for a site that is latitudinally about 1 cm posterior to the deltoid midline and longitudinally about 5 or 6 cm below the acromioclavicular joint.

One should ask patients to fold their arm across their lap. The flexed position of the arm will help to relax the deltoid. To stimulate additional relaxation of the muscle, I briefly massage the area of the muscle overlying the injection site, which makes the injection even less painful than it otherwise might have been. I found that I could not do this without touching the patient, much to the possible consternation of my mentors in academic psychology. However, I never informed them of my transgressions. The so-called Z technique used for i.m. medications that are not very viscous, such as iron preparations, is actually unnecessary since all of the decanoate preparations are sufficiently viscous to prevent significant backflow through the injection site providing the injection is slowly administered.

If patients appear unduly apprehensive and lock their eyes on the syringe, one should talk about some unrelated topic while about to administer the injection, or even about a related topic—anything to keep the eye from focusing on the needle. Most of the time, the injection will be painless and the patient will attribute great skills to the administering physician, which is one

of the hitherto unheralded advantages of administering painless injections. It is now heralded. It is not necessary to wear a white coat during this procedure.

One other afterthought which really should be a “before-thought”: Before injecting, one should pull back on the plunger to make sure the needle has not entered a blood vessel. The i.m. preparations of both haloperidol and fluphenazine are in sesame oil vehicles. Theoretically, i.v. administration could cause a fat embolus. Also, since the preparations are viscous, it can be very difficult to withdraw fluid through the perforation site of the seal if one is withdrawing from a partially evacuated vial in which the remaining fluid is under negative atmospheric pressure. To circumvent this not very serious problem, inject air into the vial before withdrawing (I am talking about injecting air into the vial, not the patient). Anyone who has trouble understanding the theory should just remember the phrase “accentuate the positive.”

The instructions in the *Physicians' Desk Reference*² for the administration of i.m. haloperidol decanoate are to administer it as a deep intramuscular injection using a 21-gauge needle and to administer no more than 3 cm³ at any one injection site. Contrary to popular belief, it is not necessary to administer fluphenazine decanoate as an i.m. dose. It can be administered subcutaneously if that is preferred, although I prefer the i.m. route for doses greater than 1 cm³. Since fluphenazine decanoate can be administered subcutaneously, it is possible to administer it using a 5/8-inch 22-gauge needle for those patients who have a phobia about long needles or are exquisitely sensitive to pain.

There is an additional problem with haloperidol decanoate: it comes in 2 concentrations, 50 mg/cm³ and 100 mg/cm³. When I have administered the 100-mg/cm³ dose, I have noticed the kind of reactions that the authors describe with haloperidol (“Only patients who received haloperidol tended to experience pain 2 days after the injection”^(p858)). It could be that the authors were using the 100-mg/cm³ preparation, although this is not clarified in the article. I have never had the problem of lingering pain with haloperidol decanoate in the 50-mg/cm³ preparation or with the fluphenazine decanoate preparation. If the authors are having problems such as this with zuclopenthixol and flupenthixol, perhaps these preparations are too concentrated.

Finally, I would fault the psychiatrists for not administering the i.m. medications personally. I will acknowledge that the reluctance of the authors to directly administer the i.m. medications may be partially attributable to the generalized disinclination of psychiatrists to be involved in a procedure that is regarded as invasive or intrusive. However, if they are going to do a study on the painful aspects of i.m. injections, then the physicians should have been the injectors; they would have learned much more about how pain is related to injection techniques. I believe that they paid too much attention to pencil-and-paper patient assessment tools and not enough time to the nuts and bolts of medication administration.

In fact, there is much to be learned when psychiatrists go to the trenches with the syringes in their own hands. In the administration of long-acting depot medications to deltoid and gluteus, the psychiatrist's nose comes in close proximity to armpit and crotch, affording an exquisite appreciation of the patient's baseline with respect to grooming and personal hygiene. Nowhere else in psychiatry is this degree of juxtaposition of nose and crotch professionally acceptable. This information, along with the subtle changes in mental status that accompany the early phases of an exacerbation, can be utilized by the psychiatrist to titrate dosages. Sometimes, the early phases of deterioration in self-care can be inferred from the persistence of a band-aid that was applied 2 weeks earlier. At other times, the

changes are not so subtle, as when the patient offers his or her arm but is too preoccupied to roll up his or her sleeve. Such clues are not offered with gluteal administrations.

In addition, the administration of intramuscular depot preparations has had some unexpected beneficial side effects, not the least of which is that the use of the syringe contributes to the image of the psychiatrist as being at home with modern medical technology and all that this implies in terms of the epidemiologic control of a biological illness. If the psychiatrist's hand was the hand that held the syringe, he or she would have learned this.

Dr. Fleishman reports no financial affiliation or other relationship relevant to the subject matter of this letter.

REFERENCES

1. Bloch Y, Mendlovic S, Strupinski S, et al. Injections of depot antipsychotic medications in patients suffering from schizophrenia: do they hurt? [CME] *J Clin Psychiatry* 2001;62:855-859
2. Haldol Decanoate (haloperidol). *Physicians' Desk Reference*. Montvale, NJ: Medical Economics; 2002:2535-2537

Martin Fleishman, M.D., Ph.D.
St. Francis Memorial Hospital
San Francisco, California

Dr. Bloch Replies

Sir: My colleagues and I thank Dr. Fleishman for his interest in our work¹ and for sharing his personal experience in treating patients with depot antipsychotic medications.

We were amazed to find that he considers that “the impact of the article inevitably will be to discourage physicians from using i.m. injectable medications.” If this is the inference other readers have made, we are indebted to him for helping us clarify this topic. Our interest in the use of depot antipsychotics comes from our clinical experience considering the efficiency of this therapy. It was our impression that the pain caused by injections is one of the reasons that some patients are reluctant to use this therapy. Thus, our study¹ aimed to investigate this clinical observation. In the study, our patients graded the pain from the index injection at 2.61 on a scale from 0 to 10, i.e., mild pain (no “intense pain” as Dr. Fleishman misinterpreted). Since our patients have received depot injection for prolonged periods of time, and we suspected that asking about the pain of the index injection might induce its report, we also inquired about “the worst pain they ever had from an injection” (a concept that might have confused Dr. Fleishman). The “worst pain ever” was 5.1, i.e., moderate in severity. Still, the severity of this “mild to moderate” pain was found in our study to correlate with the patients' attitude toward the injection. This, in our view, is an important finding because it implies that discovering means to ease the pain will ameliorate this attitude. We are now analyzing our results from a second double-blind crossover study in which a local anesthetic was used to ease the pain caused by injection of antipsychotic medications. The primary results seem to support the use of this technique.

Concerning the technique of i.m. injections, there exists a body of evidence, mainly in the field of nursing^{2,3} but also in this journal,⁴ that might be relevant and aid the reader. We used a 21-gauge needle (as recommended). The haloperidol decanoate concentration was 100 mg/mL; this is a possible explanation for the existence of pain 2 days after injection as Dr. Fleishman suggests, but (as we discussed in our article) there

was no clinical evidence of “injection site reaction,” a phenomenon probably related to the concentration.⁴⁻⁶ We used in our study the work of our staff nurse due to her vast experience and both practical and theoretical acquaintance with the technique of i.m. injections and more importantly due to the fact that we aimed at examining common practice, i.e., i.m. injections by nurses.⁴

Dr. Fleishman faults psychiatrists for “not administering i.m. injections personally,” and claims that “the use of the syringe contributes to the image of psychiatrist as being at home with modern medical technology.” I question these claims. First, most other medical professionals, e.g., pediatricians and internists, do not feel the personal need to inject the i.m. medications, and sometimes (especially in my experience with paranoid patients) the division between decision (to order an injection) and practice (to give the injection) helps compliance. Still, if Dr. Fleishman can substantiate these interesting claims, I will be more than willing to reexamine my personal practice.

A technical remark relates to the fact that although the deltoid is a more convenient site for injection, especially in a physicians' bureau, most patients and caregivers claim that since it is a smaller muscle with less tissue, it is a more painful and problematic site for i.m. injections. Still, some argue differently,⁴ but this claim, too, should be investigated.

Last, but not least, I would like to relate to my colleague's final and “conceptual” remarks. I think that what makes psychiatry a distinguished medical profession is not “the hand holding

the syringe,” but the interest and care involved in examining common clinical practices, studying them meticulously with the tools offered by clinical research, and trying to find insights and solutions that can ameliorate our everyday practice. I hope that our work with depot injections will have its humble contribution to our practice.

REFERENCES

1. Bloch Y, Mendelovic S, Strupinski S, et al. Injections of depot antipsychotic medications in patients suffering from schizophrenia: do they hurt? [CME] *J Clin Psychiatry* 2001;62:855-859
2. Quartermaine S, Taylor R. A comparative study of depot injection techniques. *Nurs Times* 1995;91:36-39
3. Mac Gabhann L. A comparison of two depot injection techniques. *Nurs Stand* 1998;12:39-41
4. Maharaj K, Guttmacher LB, Moeller R. Haloperidol decanoate: injection site reactions [letter]. *J Clin Psychiatry* 1995;56:172-173
5. Hamann GL, Egan TM, Wells BG, et al. Injection site reactions after intramuscular administration of haloperidol deconate 100 mg/mL. *J Clin Psychiatry* 1990;51:502-504
6. Reinke M, Wiesert KN. High incidence of haloperidol decanoate injection site reactions [letter with reply]. *J Clin Psychiatry* 1992;53:415-416

Yuval Bloch, M.D.
Shalvata-Mental Health Center
Hod Hasharon, Israel