

Letters to the Editor

Rectal Antidepressant Medication in the Treatment of Depression

Sir: In recent years, advances in gastrointestinal surgery and the ability to support patients on total parenteral nutrition have led to the withdrawal of oral medications for extended periods of time in more and more patients. Depression can be a significant issue in some of these patients. As most of the antidepressants are available only as oral preparations, alternate routes of administration must be used if an antidepressant is to be continued or initiated.

The rectal route of administration is considered infrequently in adults. However, it provides an effective access route when other routes are unavailable or impractical.¹ Absorption from the rectal mucosa is rapid and reliable.² Although few medications are available in suppository form, skilled pharmacists are readily able to make suppositories from many oral medications.³ For the depressed patient who cannot use oral medication, needs an antidepressant, and cannot tolerate the two available injectable antidepressants (imipramine and amitriptyline) because of side effects or excess volume of injection, the rectal route can be helpful. The following case demonstrates the use of rectal antidepressant medication.

Case report. Mr. A, a 42-year-old man, was admitted with bowel obstruction related to a history of excision of pancreatic pseudocyst and distal pancreatectomy. He had a pylorojejuno-plasty for hypertrophic pyloric stenosis that required 7 days of bowel rest. Prior to surgery, he had been on trazodone 200 mg orally at bedtime for major depression, recurrent type. In the past, he had noted increased depression when off trazodone for a period of a week. On the third postoperative day, he requested to see psychiatry because of his concern that his depression would return. He was found to have depressed mood and affect and wished to resume trazodone therapy. He agreed to the use of a suppository to deliver the trazodone dose. This was begun on the fourth postoperative day. By the sixth postoperative day, he reported improved mood and better sleep. He was able to resume oral medication by his eighth postoperative day.

While this was a fairly rapid response to trazodone and may represent a response to the hypnotic rather than the antidepressant effect of trazodone, the usefulness of the rectal route is demonstrated. Other antidepressants could be administered by the same route.³⁻⁵ Initiation of antidepressant medication by the rectal route should also be considered when symptoms or diagnosis indicates need in the patient without oral intake.

Various pitfalls may be encountered in the use of rectal medications. Some patients may not wish to use rectal medications for psychological reasons and may misinterpret the administration of rectal medication. Some medications may be irritating and difficult to retain. Positioning of the suppository may alter absorption.^{1,2}

Rectal administration of antidepressant medications has been little studied physiologically or psychologically.³⁻⁵ As we are able to sustain patients for long periods of time without oral intake and are more sensitive to the need for antidepressants, a better understanding of the rectal route is warranted.

REFERENCES

1. Warren DE. Practical use of rectal medications in palliative care. *J Pain Symptom Manage* 1996;11:378-387
2. van Hoogdalem EJ, de Boer AG, Breimer DD. Pharmacokinetics of rectal drug administration, I: general considerations and clinical applications of centrally acting drugs. *Clin Pharmacokinet* 1991;21:11-21
3. Holmes TF, Sabaawi M, Fragala MR. Psychostimulant suppository treatment for depression in the gravely ill [letter]. *J Clin Psychiatry* 1994;55:265-266
4. Storey P, Trumble M. Rectal doxepin and carbamazepine therapy in patients with cancer. *N Engl J Med* 1992; 327:1318-1319
5. Adams F. Amitriptyline suppositories [letter]. *N Engl J Med* 1982;306:996

Marlene M. Mirassou, M.D.
Sacramento, California

Risperidone-Induced Tardive Dyskinesia

Sir: I present a case of risperidone-induced tardive dyskinesia that is unusual because the patient had never been treated with the typical antipsychotics and the dose of risperidone was only 1 mg/day. During his withdrawal, symptoms fluctuated in an inverse relationship with the increase and decrease of risperidone dose.

Case report. Mr. A, a 50-year-old divorced white man, has been receiving psychiatric treatment for 16 years. He suffers from recurrent major depression and was hospitalized twice in the past 5 years with suicidal ideation. In addition to various antidepressants, he was tried for short periods of time on lithium, carbamazepine, and divalproex sodium with no discernible benefit. In the spring of 1996, after unsuccessful trials of paroxetine and nefazodone, he was started on fluvoxamine 50 mg/day and risperidone 0.5 mg h.s. A month later, risperidone was increased to 1 mg h.s., and fluvoxamine was slowly increased to 200 mg/day.

In the fall of 1996, because Mr. A was no better, fluvoxamine was tapered off, and he was given fluoxetine 40 mg/day with which he was treated successfully a few years earlier. Risperidone 1 mg/day was continued. In late November 1996, he showed blinking of the eyes, parkinsonian tremor of the hands, and some tongue-rolling movements. Risperidone was stopped and fluoxetine reduced to 20 mg/day. Gradually, the abnormal movements worsened, and a month later the blinking was so frequent and constant that he was not able to read, watch television, or drive his car. His respiration became labored and deep with occasional high-pitched vocal sounds during expiration. He was restarted on risperidone 0.5 mg h.s., and a month later clorazepate 15 mg/day in divided dosage was added.

His symptoms improved minimally, but he developed suicidal impulses and was rehospitalized for 8 days in January 1997. His symptoms were suppressed with increased dosage of risperidone 2 mg/day and fluoxetine 40 mg/day. Another attempt was then made to withdraw risperidone. Blepharospasm and labored breathing returned. He also started to make cluck-

ing sounds with his tongue. The clucking sounds occurred about every 10 seconds and were suppressed when he was either talking or singing. A few weeks later, the vertical movements of the tongue changed to rapid transverse movements, at the rate of about 3 or 4 per second, one centimeter in each direction from the midline.

In mid-March 1997, at Mr. A's request, in spite of the persistent side effects, risperidone treatment was stopped. He was continued on fluoxetine 40 mg/day, the dose of clorazepate was increased to 30 mg/day, and perphenazine 4 mg t.i.d. was added. This regimen slowed the horizontal tongue movements to about 1 per second, and the blinking of the eyes became intermittent. One month later, reserpine 0.25 mg b.i.d. was added to the above medications with marked relief in symptoms. The tongue movements changed to the classical tongue rolling of tardive dyskinesia. The blinking of the eyes almost disappeared, and there was only occasional deep and labored breathing. Perphenazine was tapered off over the next month. At the end of May, he complained of worsening depression with crying spells lasting 1–2 hours at a time. Reserpine was tapered off and dyskinetic movements became worse. Perphenazine had to be restarted. Three months later, he was receiving perphenazine 4 mg q.i.d., fluoxetine 20 mg b.i.d., and clorazepate 7.5 mg q.i.d. He still had tongue rolling movements with pushing of the left cheek, some puckering of the lips, and occasional deep sighing respirations. Mr. A denied being depressed and had enrolled in two college courses.

The severity of dyskinetic movements generally correlated with the depth of depression, except when he was taking reserpine. While he was taking reserpine 0.25 mg b.i.d., the dyskinesia was in reasonable control, but the depression was worse.

Risperidone, a newer antipsychotic agent, is classified as an atypical agent because it has a low $D_2/5\text{-HT}_2$ binding ratio and a lower incidence of extrapyramidal side effects compared with typical antipsychotics. It is too early to judge its potential for causing tardive dyskinesia. There have been isolated case reports of patients who were treated with typical antipsychotics in the past who developed tardive dyskinesia when they were treated with a dosage of risperidone 6 mg or higher.^{1–4} Mr. A had never before taken antipsychotics, and he only took risperidone 1 mg/day for 6 months. An unusual presentation was the variety of tongue movements. The progression from slight tongue rolling to slow, large amplitude vertical movements to rapid small amplitude horizontal movements and finally to tongue rolling suggests that, in an acute phase, the tongue-rolling dystonic movements can split into two components of vertical and horizontal movements. The three predisposing factors in this case were age, diagnosis of depression, and concomitant use of fluoxetine. Fluoxetine would have increased the blood levels of risperidone and could also have enhanced extrapyramidal symptoms by altering the central dopamine/serotonin ratio in the nigrostriatal system. Fluoxetine itself has been implicated in the causation of tardive dyskinesia.⁵

On the basis of its data, the Janssen Pharmaceutical Research Foundation estimates that the risk of tardive dyskinesia in patients receiving risperidone is 0.0034 per treatment year.⁶ Compared with typical antipsychotics, risperidone is less likely to cause tardive dyskinesia, but the risk does exist.

REFERENCES

1. Addington DE, Toews JA, Addington JM. Risperidone and tardive dyskinesia: a case report [letter]. *J Clin Psychiatry* 1995;56:484–485
2. Buzan RD. Risperidone-induced tardive dyskinesia [letter]. *Am J Psychiatry* 1996;153:734–735
3. Anand VS, Dewan MJ. Withdrawal-emergent dyskinesia in a patient on risperidone undergoing dosage reduction. *Ann Clin Psychiatry* 1996;8:179–181
4. Woerner MG, Sheitman BB, Lieberman JA, et al. Tardive dyskinesia induced by risperidone? [letter] *Am J Psychiatry* 1996;153:843
5. Dubovsky SL, Thomas M. Tardive dyskinesia associated with fluoxetine. *Psychiatr Serv* 1996;47:991–993
6. Ayd FJ Jr, Pies RW. A specific comparison of the atypical antipsychotics. *Advances in Psychopharmacology* 1997:61–62

Brij M. Saran, M.D., Ph.D.
Gloversville, New York

Naltrexone-Induced Reduction of Tobacco Intake

Sir: Naltrexone is an opioid blocker that may alter taste perception. We present the cases of two patients, both of whom smoked heavily and were opiate dependent, who spontaneously and rapidly reduced their daily tobacco intake when undergoing naltrexone treatment.

Case 1. Mr. A, a 28-year-old man, had smoked approximately 50 cigarettes per day for 14 years and had never tried to quit. He started smoking at the age of 14 and abusing heroin at the age of 23. Ten days after completing opiate detoxification, he started naltrexone 50 mg/day. From the third day of naltrexone treatment, he reported less desire to smoke and a slight reduction in food intake. After 1 week, Mr. A reported an abrupt reduction in cigarette smoking (to around 5 per day), which was attributed to an inability to taste tobacco. He did not report nicotine withdrawal. Two months later, naltrexone was suspended for 1 week, during which the ability to taste tobacco and the desire to smoke returned. After 3 months, naltrexone was discontinued, which led to an increase in tobacco intake. The intake, however, did not reach its previous amount. At the time of this report, Mr. A has maintained his opiate-free status, continues to attend the outpatient facility, and is engaged in a smoking cessation program.

Case 2. Mr. B, a 31-year-old man, had smoked up to 40 cigarettes per day for 16 years and had made several attempts to quit, which were unsuccessful due to nicotine craving. He started smoking at the age of 15 and abusing codeine at the age of 29. Two weeks after completing detoxification, he was administered naltrexone (100 mg on Monday, 100 mg on Wednesday, and 150 mg on Friday each week). After 1 week, he reported smoking cessation, which was explained by an inability to taste tobacco. He developed a slight nicotine withdrawal syndrome that consisted of insomnia and irritability and reported a reduction in food intake. Two months later, naltrexone was suspended for 1 week, during which the previous ability to taste tobacco returned. After 6 months, naltrexone was stopped, and Mr. B started to smoke again. He was opiate-free, continued attending the outpatient facility, and was referred to a smoking cessation program.

There is some evidence of the efficacy of naltrexone for smoking cessation.¹ Naltrexone may alter taste perception and nutrient intake in humans, perhaps through endogenous opioid release.² Our patients reduced smoking and food intake due to an inability to taste nicotine and food. We think that naltrexone may affect the ability to taste nicotine and thus may be useful in some cases of nicotine dependence in diminishing smoking reinforcement and in facilitating smoking cessation programs. However, the results we observed suggest the need for con-

trolled studies to confirm the effectiveness of this pharmacologic approach.

REFERENCES

1. Covey LS, Glassman AG, Stetner F. Naltrexone for smoking cessation. In: Proceedings of the 9th Annual Conference of the American Society of Addiction Medicine; November 14–17, 1996; Washington, DC. Abstract No. 21A
2. Bertino M, Beachamp GK, Engelman K. Naltrexone, an opioid blocker, alters taste perception and nutrient intake in humans. *Am J Physiol* 1991;261(1 pt 2):R59–R63

Arturo G. Lerner, M.D.
Igor Oyffe, M.D., Ph.D.
Mircea Sigal, M.D.
Netania, Israel

Leukopenia Associated With Addition of Paroxetine to Clozapine

Sir: Clozapine is an atypical antipsychotic agent used primarily in the management of otherwise treatment-refractory psychotic patients.¹ Its use carries a high risk of leukopenia (WBC < 3000/mm³), usually within 6–12 months, and a 1% to 2% risk of potentially fatal agranulocytosis (< 500 neutrophils/mm³) that leads to the current requirement of weekly WBC monitoring.^{1,2} The basis of the suppression of neutrophils by clozapine is unknown. It may not represent direct toxicity since there is little evidence of a dose-risk relationship, and an immunological mechanism has been postulated.^{2,3} Nevertheless, in vitro cytotoxicity of clozapine and particularly its metabolite norclozapine can occur,² and pharmacologic factors including cotreatment with other antipsychotics or removal of the leukocyte-stimulating agent lithium may increase the risk of clozapine-associated leukopenia.^{2,4} We now report a possible association between the addition of the serotonin reuptake inhibitor (SRI) paroxetine to prolonged safe use of clozapine and the rapid emergence of severe leukopenia.

Case 1. Ms. A, a 38-year-old white woman with schizoaffective illness, was maintained on 300 mg of clozapine for 12 months, with a stable WBC (4000–6000/mm³), as well as sertraline (150 mg), valproate sodium (1 g), and (–)-thyroxine (75 µg) daily. She was rehospitalized for 2 weeks for suicidal depression. The SRI was changed from sertraline to paroxetine (50 mg), and the daily dose of clozapine increased slightly (to 350 mg); valproate was unchanged and thyroxine discontinued. Two weeks after Ms. A was discharged, the WBC was 3500/mm³ (1925 neutrophils/mm³), and it fell to 2600/mm³ (806 neutrophils/mm³) a week later. Clozapine was stopped abruptly and uneventfully, with a rapid return of the WBC to a stable level of 4000–5000/mm³ within 28 days, as risperidone (6 mg) was added daily, and paroxetine continued.

Case 2. Ms. B, a 57-year-old white woman with schizoaffective psychosis with major depression, was given clozapine (450 mg) for 6 months, with a stable WBC (4000–6000/mm³), lorazepam (5 mg), benzotropine (1.5 mg), and amitriptyline (100 mg; serum levels at 200–250 ng/mL) daily, following uneventful but unsuccessful trials of fluoxetine and sertraline. Lack of response of depression led to a change of antidepressant to paroxetine (10 mg) daily, with WBC at 5500/mm³ (3300 neutrophils/mm³). Two weeks after paroxetine was added, WBC fell to 3300/mm³ (1900 neutrophils/mm³) and to 2900/mm³ (1430 neutrophils/mm³) 7 days later, and clozapine was stopped. Within 21 days of a switch to chlorpromazine (400 mg daily) during

which paroxetine was continued, the WBC returned to 4000–6000/mm³.

The findings described are provisional, but these two cases may represent an early warning that a rapidly emerging leukopenia may occur after the addition of the SRI paroxetine to stable regimens of clozapine. In both cases, clozapine had been well tolerated hematologically for 6–12 months, relatively late in the period of high risk of clozapine-induced leukopenia.^{1,2} Other SRIs (sertraline and fluoxetine) had been well tolerated in both cases, and WBC normalized while paroxetine treatment was continued without clozapine. This lack of an effect of paroxetine alone on WBC accords with the literature⁵ and a MEDLINE search through December 1997. It may be that the observed association is merely a coincidence and an unusually late-emerging reaction to clozapine itself.

Assays of circulating concentrations of clozapine were not available, but several SRIs can elevate serum levels of clozapine and norclozapine by 40%–50%, and sometimes > 1000 ng/mL, with the greatest risk found with paroxetine, and the least risk with sertraline.^{6,7} The reported general lack of association of risk of leukopenia and dose or serum level of clozapine or norclozapine^{2,3} may not be absolute, and a sharp increase in drug levels may have contributed to risk in the cases reported. Alternatively, paroxetine may have other leukopenia-potentiating effects. These two cases do not allow the conclusion that there is a specific risk of marrow toxicity due to the combination of paroxetine with clozapine. Nonetheless, clinical prudence suggests extra caution with this combination until the hypothesized risk of this drug combination is investigated thoroughly in a controlled study.

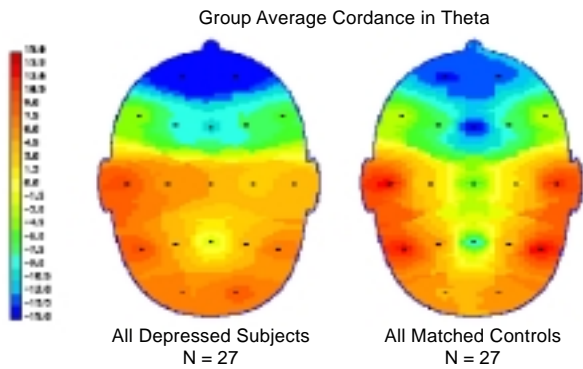
Supported in part by a Physician-Scientist Award from the Lucille P. Markey Trust and a Young Investigator Award from NARSAD (Dr. George); the Stanley Foundation Research Awards Program (Dr. Sernyak); and USPHS (NIMH) grant MH-47370 and awards from the Bruce J. Anderson Foundation and the McLean Private Donors Neuropharmacology Research Fund (Dr. Baldessarini).

REFERENCES

1. Baldessarini RJ, Frankenburg FR. Clozapine: a novel antipsychotic agent. *N Engl J Med* 1991;324:746–754
2. Mendelowitz AJ, Gerson SL, Alvir JMJ, et al. Clozapine-induced agranulocytosis: risk factors, monitoring and management. *CNS Drugs* 1995;4:412–421
3. Centorrino F, Baldessarini RJ, Flood JG, et al. Relation of leukocyte counts during clozapine treatment to serum concentrations of clozapine and metabolites. *Am J Psychiatry* 1995;152:610–612
4. Godleski LS, Sernyak MJ. Agranulocytosis after addition of risperidone to clozapine treatment. *Am J Psychiatry* 1996;153:735–736
5. Boyer WF, Blumhardt CL. The safety profile of paroxetine. *J Clin Psychiatry* 1992;53(2, suppl):61–66
6. Centorrino F, Baldessarini RJ, Frankenburg FR, et al. Serum levels of clozapine and norclozapine in patients treated with selective serotonin reuptake inhibitors. *Am J Psychiatry* 1996;153:820–822
7. Meyer M, Baldessarini RJ, Goff D, et al. Clinically significant interactions of psychotropic drugs with antipsychotic agents. *Drug Saf* 1996;15:333–346

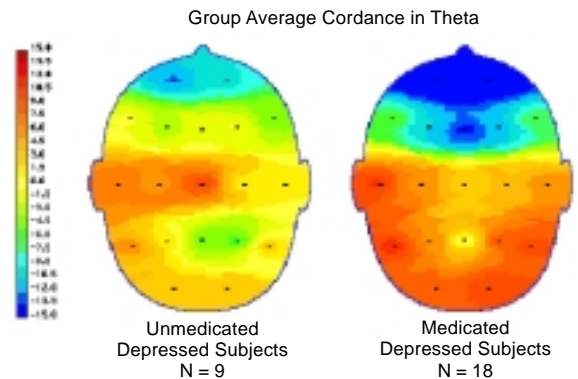
Tony P. George, M.D.
Linda Innamorato, R.N.C.
Michael J. Sernyak, M.D.
New Haven, Connecticut
Ross J. Baldessarini, M.D.
Franca Centorrino, M.D.
Belmont, Massachusetts

Figure 9. Average Cordance Maps for Depressed and Control Subjects*



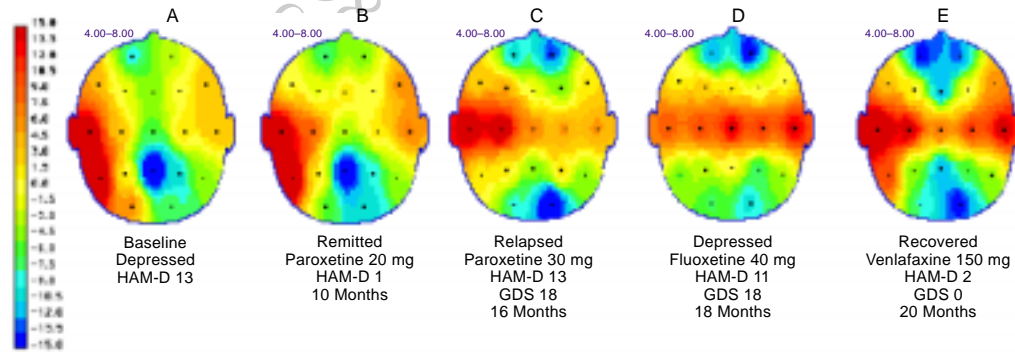
*Adapted from Cook et al.⁵⁵ Depressed subjects show a disruption of the normal antero-posterior gradient, with lower cordance values in the frontal regions (indicated by blue-green colors) and decreased cordance in the temporal regions, which is most marked on the right. Cordance maps show the head as viewed from above, with red colors indicating higher cordance values and blue colors indicating lower cordance values.

Figure 10. Average Cordance Maps for Subjects Not Receiving and Receiving Antidepressant Medications*



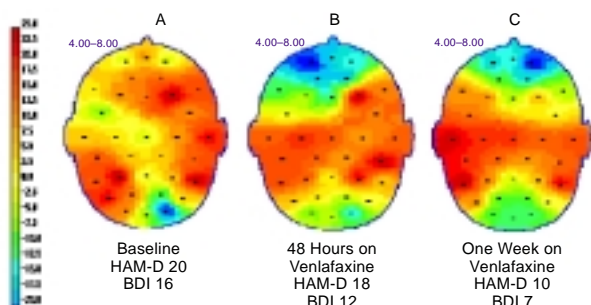
*Adapted from Cook et al.⁵⁵ Subjects not receiving medication show a marked loss of the normal antero-posterior gradient, while subjects receiving medication show an "overcorrection" of the antero-posterior gradient. This finding suggests that antidepressant treatment is associated with relative suppression of frontal brain activity.

Figure 11A–11E. Series of Cordance Maps From a Subject Undergoing Treatment for Depression*



*At baseline (A), subject had low cordance over the frontal regions and the right temporal region. Although symptoms resolved after treatment with paroxetine (B), the frontal cordance did not decrease further and the temporal cordance did not increase. The subject relapsed, and an increased dose of paroxetine did not resolve the depression (C). Fluoxetine in a dosage up to 40 mg also was ineffective (D). Finally, the subject was treated with venlafaxine, which led to a complete remission of symptoms. The cordance map showed a large bilateral decrease in frontal cordance and a bilateral increase in temporal cordance, consistent with effective treatment (E). Abbreviations: GDS = Yesavage Geriatric Depression Scale; HAM-D = Hamilton Rating Scale for Depression.

Figure 12A–12C. Series of Cordance Maps From a 32-Year-Old Female Subject, Recorded During the First Week of Venlafaxine Treatment*



*Subject started to show resolution of depressed cordance pattern as early as 2 days after medication was started (B), before clinical symptoms improved. The cordance continued to decrease over the next week as depression scores decreased (C). Abbreviations: BDI = Beck Depression Inventory, HAM-D = Hamilton Rating Scale for Depression.

CORRECTION

In the article "Brain Structure and Function and the Outcomes of Treatment for Depression" (1997 Supplement 16, pp. 22–31) by Andrew F. Leuchter, M.D., and colleagues, Figures 9–12 on pages 29 and 30 should have appeared in color. The four color figures are reprinted here.

The staff regrets this printing error.